

Diagnosis of shoulder pain made simple

Dr Daniel Mok

17th June 2011

Shoulder Clinic - Epsom 2008

N=842

Rotator Cuff Tear	284	Impingement	77
Labral Tear	159	Dislocation/sublux	28
OA Shoulder	70	ACJ pain	56
Calcium	48	Neck	28
Frozen shoulder	24	Clavicle	20
Fracture	17	Misc (lipoma, Scap dys)	31

AGE

<40

Instability

Capsular Tear

LHB (SLAP)

ACJ subluxation/dis

>40

Cuff Tear

Adhesive Capsulitis

LHB (SLAP)

Calcific Tendinitis

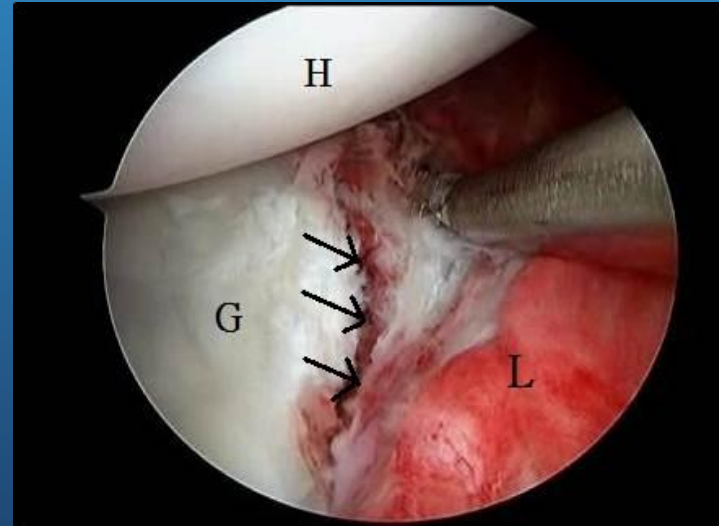
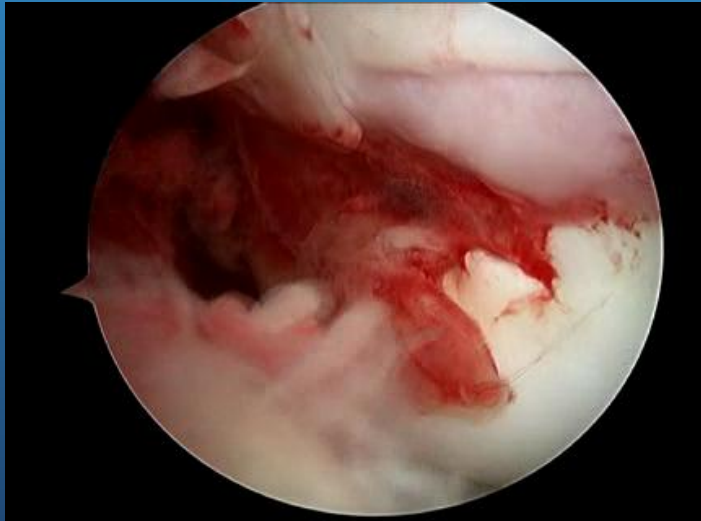GHJ arthritis

Under 40 - Instability

History of injury

Anterior shoulder pain

Positive Anterior Apprehension Test



Anterior Apprehension Test

Sensitivity 72%

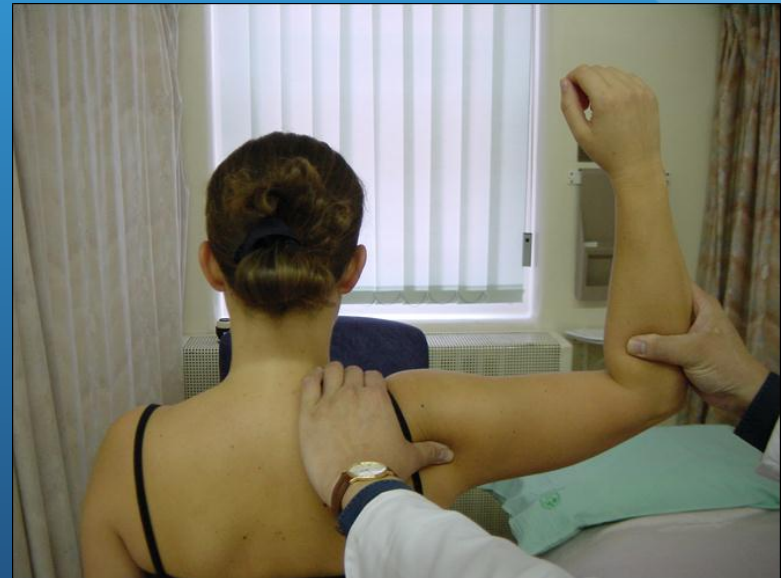Specificity 96%

Arm in 90° Abduction
+ 90° Ext. rotation

Positive Test

-Apprehension

-Pain



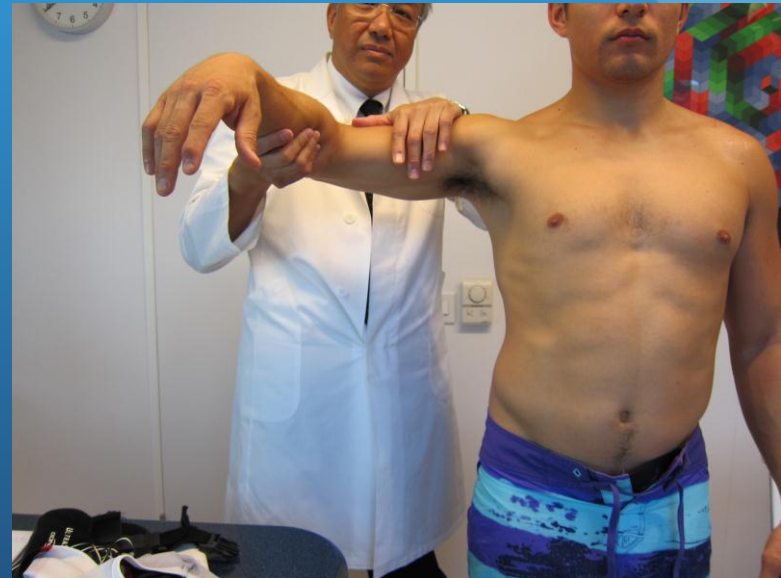Ligamentous Laxity

Beighton 1969

>6 (9)

Boileau 1999

Asymmetric
hyperabduction >20°



Under 40 - ACJ Injury

Rugby, Mountain bike

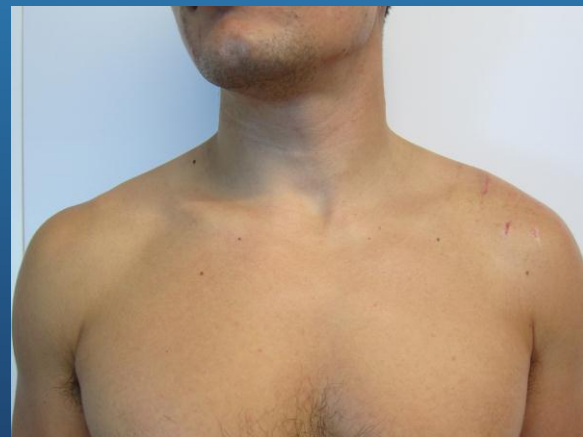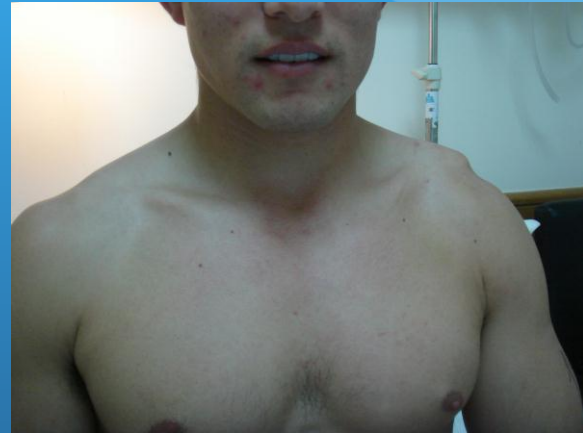History of Injury

Points to the joint

High Painful Arc

Pain on adduction

O'Brien's Test



O'Brien's Test

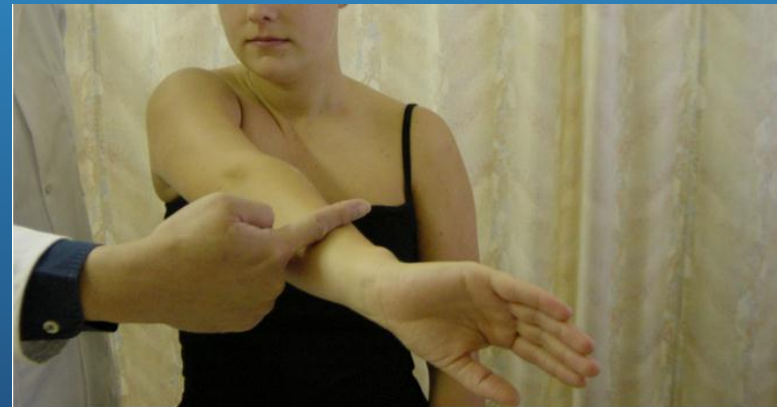Arm flexed at 90° but adducted across the sagittal plane, hand in int. rotation

Pain on resisted elevation

No pain on resisted elevation if palm supinated

Sensitivity 100%

Specificity 98.5%



> 40 - Impingement

Common, exclude other causes

Gradual onset

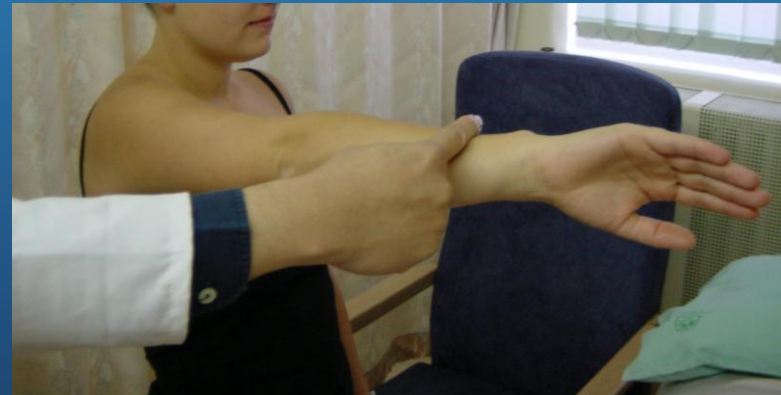Points to lateral edge of acromion

Classic painful arc 80-120

Neer Test

Internally rotated arm maximally abducted

Sensitivity 88.7% Specificity 30.5%



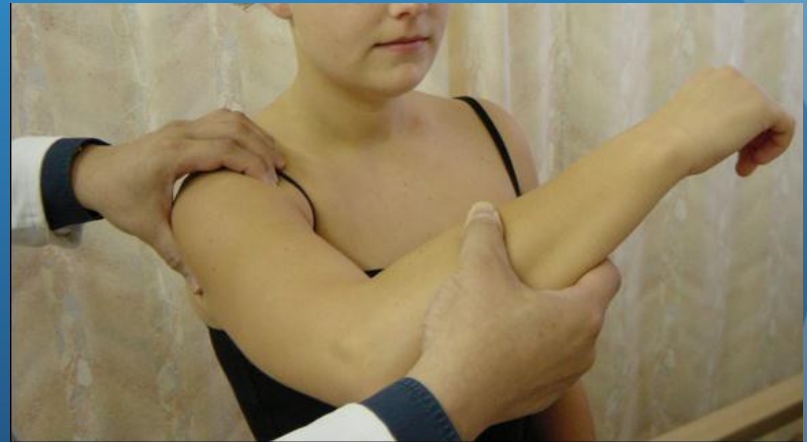Hawkin's Test

Elbow flexed 90°, int rotation in sagittal plane

Pain located in subacromial space

Sensitivity 92.1%

Specificity 25%



> 40 - Rotator Cuff Tear

50% population >66yrs

Yamaguchi 2006

33.7% new patients

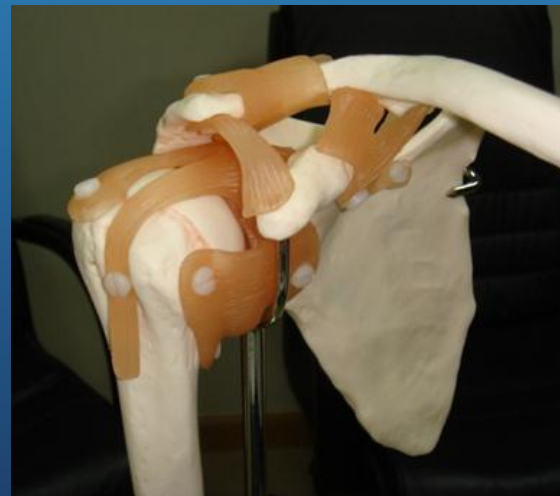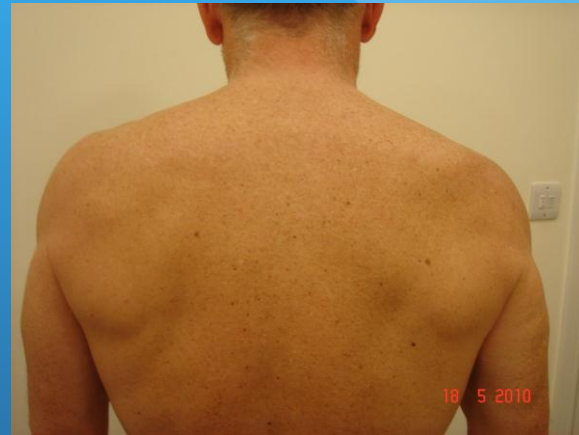Night Pain

Points to lateral arm

Lateral Jobe Positive

Painful Arc

Weak resisted ext. rotation



Lateral Jobe Test

Mok 2010

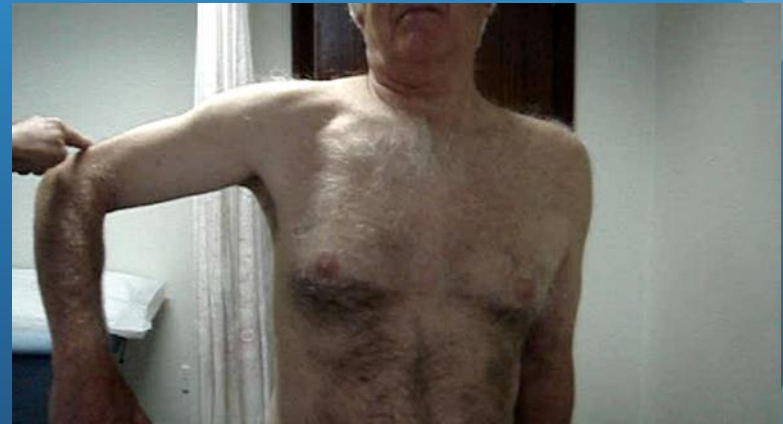
Sensitivity 81%

Specificity 89%

Arm in 90° abduction +
90° int. rotation

Unable to perform

Unable to resist
downward pressure

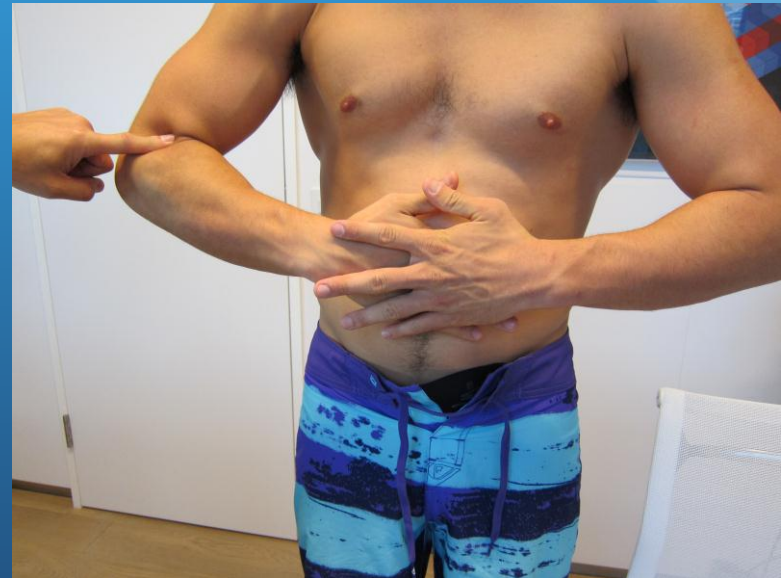

Subscapularis tear - Belly press

Points to anterior shoulder

Weak resisted internal rotation

Belly Press - hands on tummy, elbows forward. Resist push on elbow



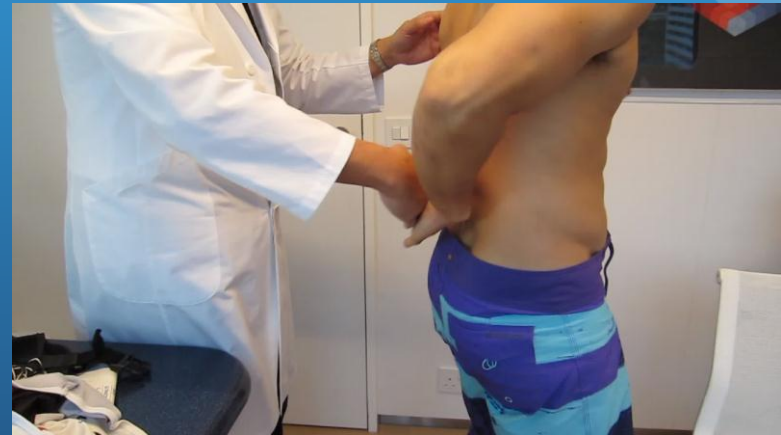Subscapularis tear - Lift off

Gerber 1991

Sensitivity 80%

Hand over back

Attempt to lift hand off



Subscapularis Tear - Yocum 1983

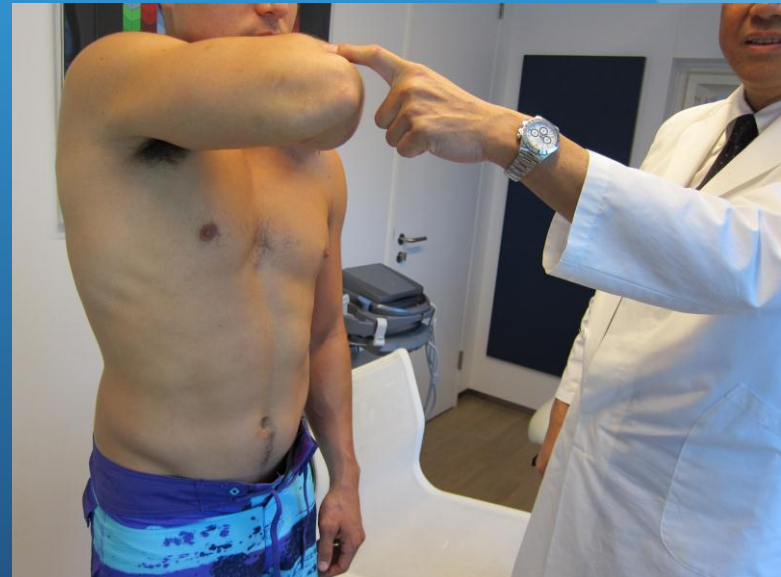Sensitivity 82% for
impingement

Hand on opposite
shoulder-

Lift elbow against
resistance

Unable to perform=

Subscapularis Tear



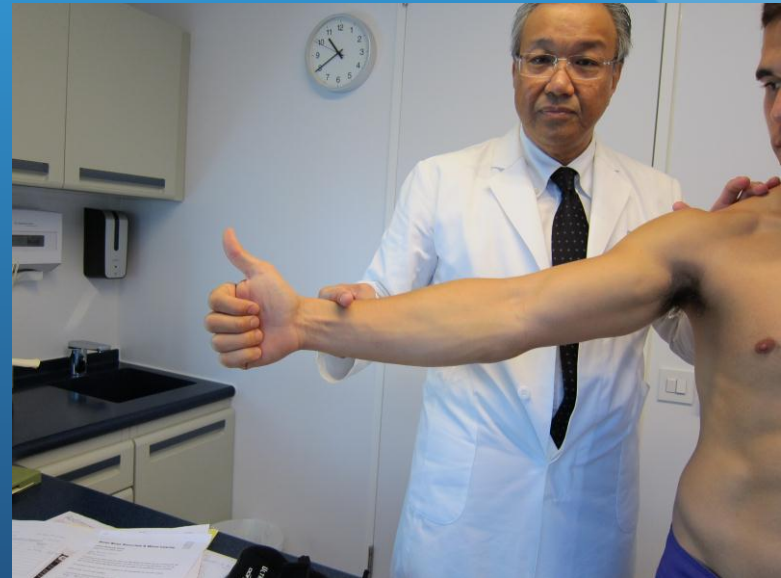Supraspinatus Tear

Empty can test (75% accurate)

Arm in 90° elevation in scapula plane, arm int. rotated

Full can test (70% accurate)

Above + arm 45° ext rotated



Massive Cuff Tear - Codman 1934

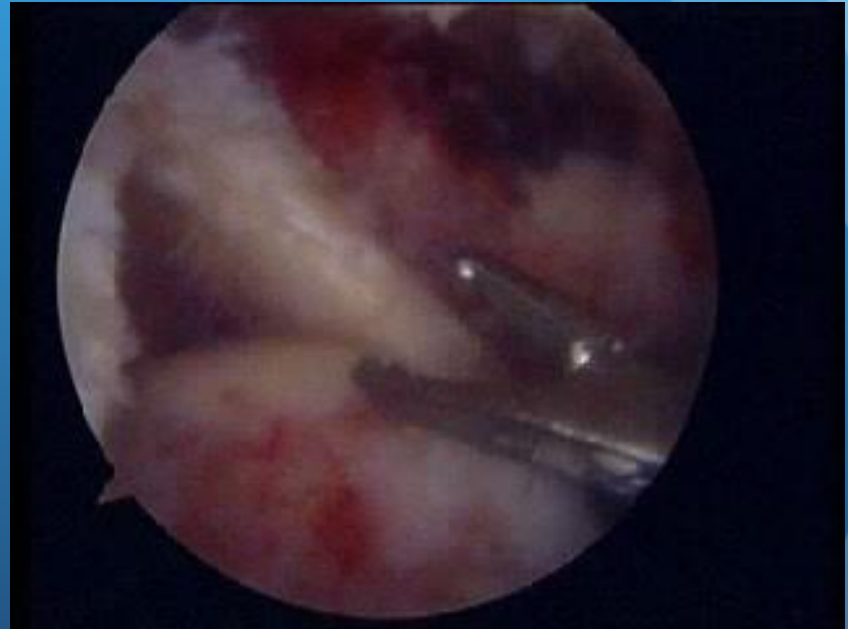Rent Test - Crepitus in subacromial Space

Sensitivity 95.7%

Specificity 96.8%

Drop Arm sign

Lifted arm up above 90°, unable to control descend



Massive Cuff Tear - Hornblower's Sign

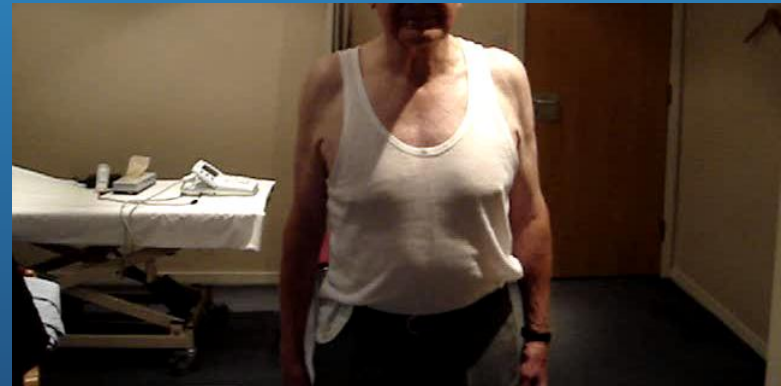
Walch 1998

Sensitivity 100%

Specificity 93%

Inability to lift the
elbow horizontal to
'blow' the horn

Irreparable teres
minor



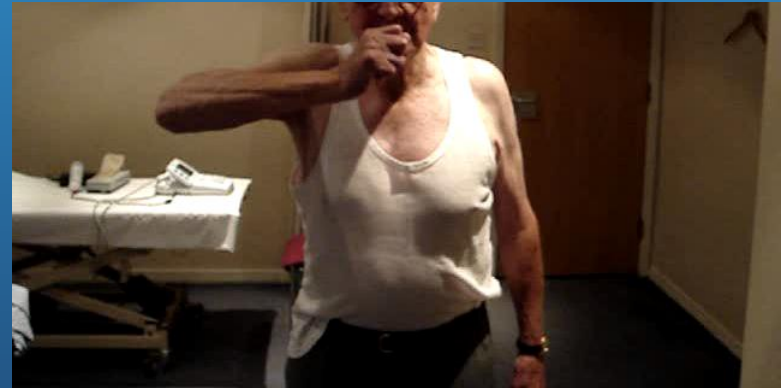
Massive Cuff Tear - Drop Sign 1998

Sensitivity 100%

Specificity 100%

Inability to hold a
flexed elbow in 45° of
Ext Rotation

Irreparable
Infraspinatus

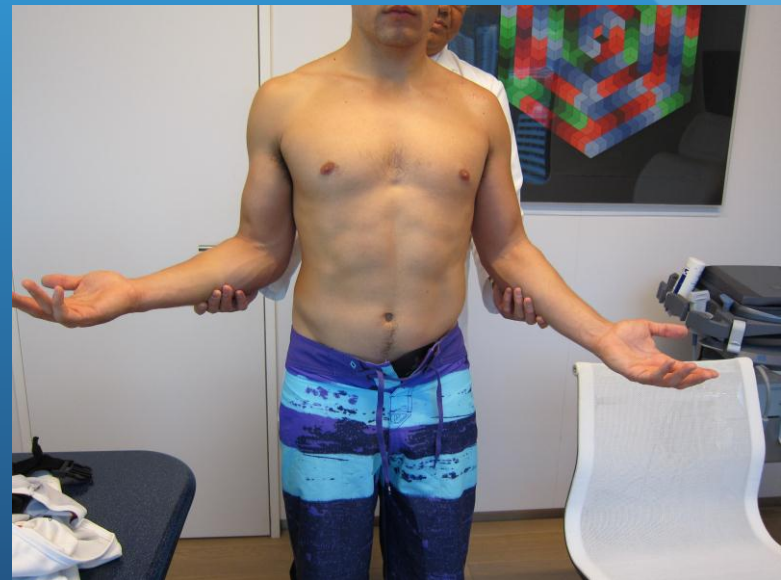

Age 50 - Adhesive capsulitis

Common

Loss of Ext. Rotation
in 2 conditions only

- Adhesive capsulitis
- Osteoarthritis



Age 40-50 Calcific Tendinitis

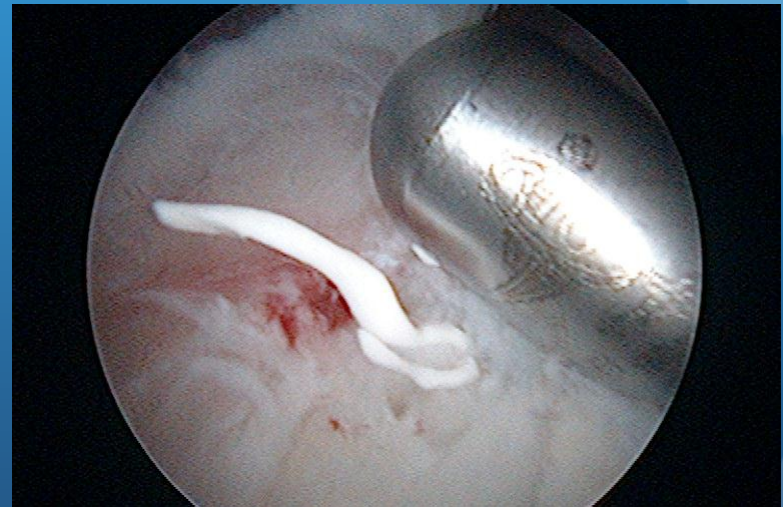
Not uncommon

Repetitive movements at
+ above shoulder

Night pain

Painful arc with palm
down

Pain relieves with palm
up



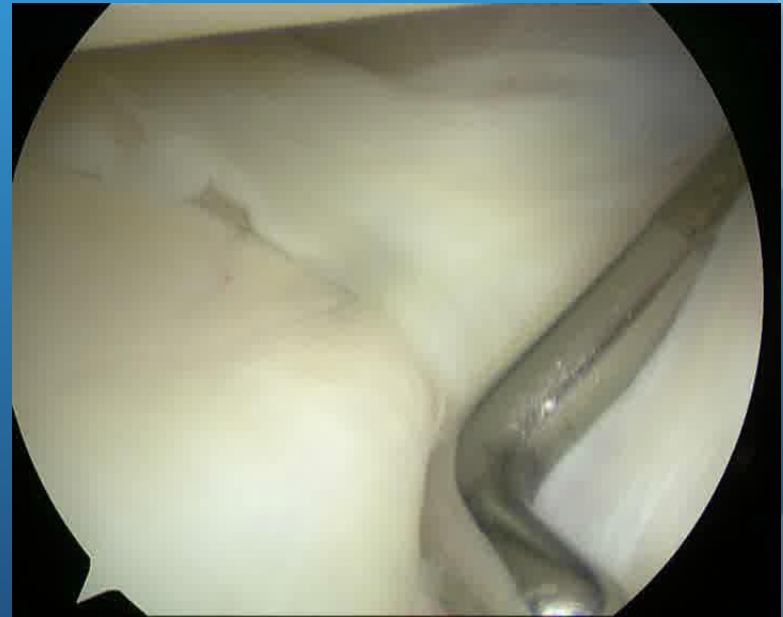Age 50 - SLAP

Biceps attachment
loose

Overload at gym or
stretch

Anterior arm pain

Worse with lifting at
'arms length'



SLAP - Compression rotation

Snyder 1990

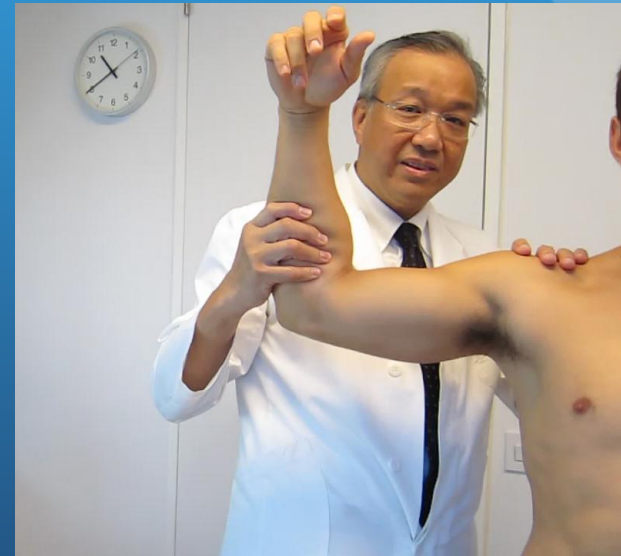Sensitivity 45%

2 / 3 Positive

O'Brien's

Anterior
Apprehension Test

Compression Rotation



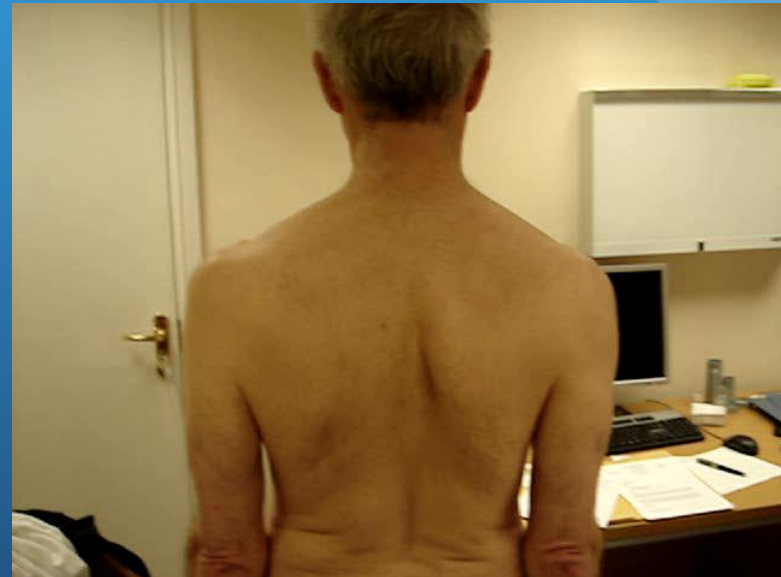Any Age - Winging

Age 40+

Pain = Neuralgic
Amyotrophy

Recent URTI

Difficult abduction



Summary

Age

History of Injury

Pain -Night

Day

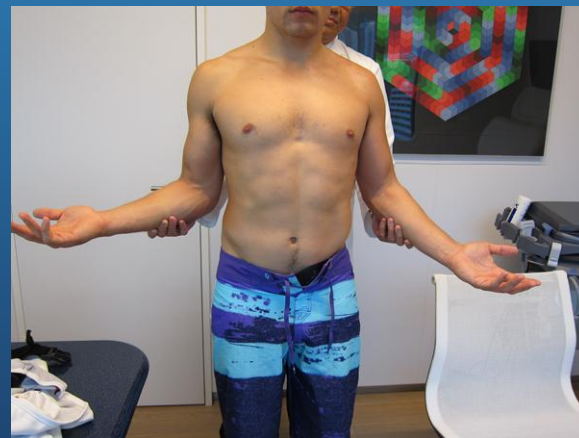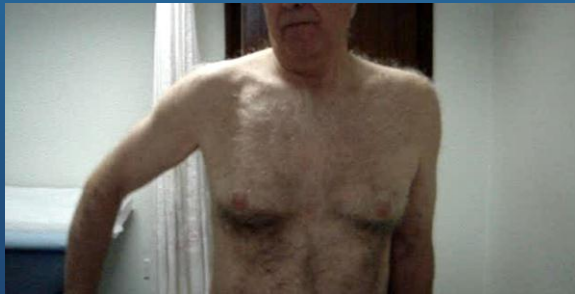
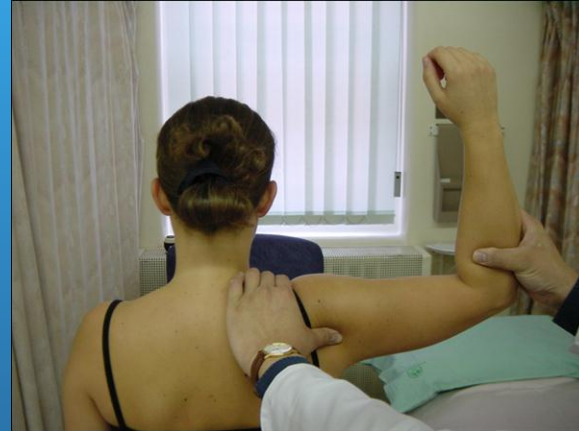Location

Loss of rotation



3 Tests

1. Anterior Apprehension Test
2. Lateral Jobe Test
3. External Rotation



Thank You



“No matter what tomorrow holds, enjoy what I have today.”